



CLINICAL CASE

Accessory soleus muscle in an athlete. Presentation of a case and a literature review



Francisco J. Rubio^{a,*}, Luis Franco^a, Manuel J. Montero^b,
Paola Ugarte^a, Alfredo Valero^a

^a *Médico Adjunto, Unitat Medicina de l'Esport, Hospital Universitari Sant Joan de Reus, Tarragona, Spain*

^b *Médico Adjunto Radiología, Hospital Universitari Sant Joan de Reus, Tarragona, Spain*

Received 10 September 2014; accepted 2 January 2015

Available online 16 February 2015

KEYWORDS

Accessory soleus muscle;
magnetic variation;
Magnetic resonance imaging

Abstract The incidence of an accessory soleus muscle, according to autopsy studies, ranged from 0.5 to 6.0% of the population.

The typical presentation is a soft mass in the posteromedial distal third of the leg, which increases in size with physical activity, especially plantar flexion. It is accompanied by pain with exercise in 67% of reported cases.

The treatment of choice is conservative, but when it causes compartment syndrome, fasciotomy should be performed. If a patient has symptoms of claudication or nerve compression, a complete excision of the muscle is required.

We report the case of an athlete who had a symptomatic accessory soleus muscle, which was studied by standard X-ray, ultrasound and magnetic resonance imaging (MRI).

© 2014 Consell Català de l'Esport. Generalitat de Catalunya. Published by Elsevier España, S.L.U. All rights reserved.

PALABRAS CLAVE

Músculo soleo accesorio;
Variación anatómica;
Resonancia magnética nuclear

Músculo soleo accesorio en una deportista. A propósito de un caso y revisión de la bibliografía

Resumen El hallazgo del músculo soleo accesorio oscila entre un 0,5 y un 0,6% de la población según los estudios necrópsicos.

La presentación típica es una tumoración blanda en el tercio distal posteromedial de la pierna, que aumenta de tamaño con la actividad física, sobre todo con la flexión plantar. Se acompaña de dolor con el ejercicio en el 67% de los casos publicados.

* Corresponding author.

E-mail address: fjrubio@grupsagessa.com (F.J. Rubio).

El tratamiento de elección es conservador, pero cuando provoca un síndrome compartimental se debe realizar la fasciotomía y, en el caso de tener síntomas de claudicación o compresión nerviosa, se necesitará una escisión completa del músculo.

Presentamos el caso clínico de una deportista que presenta un músculo soleo accesorio sintomático que fue estudiado mediante radiología, ecografía y resonancia magnética nuclear. © 2014 Consell Català de l'Esport. Generalitat de Catalunya. Publicado por Elsevier España, S.L.U. Todos los derechos reservados.

Case presentation

A 31-year-old ultra endurance runner with no history of previous trauma presented with a 2-month history of pain and swelling in the ankle and pain with exercise that adversely affected training and competition.

On physical examination, palpation reveals a soft non-pulsatile tumor in the medial malleolar ankle region, more apparent with resisted plantar flexion and toe raising. Pain was also elicited with contraction exercises and stretching of the soleus muscle. The Achilles tendon was normal in both thickness and structure and the range of motion of the ankle was normal. There were no changes in the alignment of the hindfoot. Additional tests were performed including X-ray, ultrasound and MRI of the ankle. Standard X-ray (Fig. 1) shows obliteration of the Kager triangle by a soft tissue mass. Ultrasonography, confirmed the existence of a well-defined, isoechoic, retro-calcaneal skeletal muscle mass.

MRI identified a retro-calcaneal accessory muscle structure, which originates in the soleus muscle itself and attaches to the medial calcaneal tendon (Figs. 2 and 3). The patient was diagnosed with compartment syndrome by the presence of an accessory soleus muscle. The clinical symptoms may be influenced by the compression of the posterior tibial artery and less frequently the posterior tibial nerve (Fig. 2).

Once diagnosed, treatment included orthotics, stretching the soleus muscle and reduced physical activity. When the patient was completely asymptomatic, usual physical activity was allowed, however the pain returned after running more than 20 min. Given the persistence of pain and inability to return to usual activity following conservative treatment, fasciotomy of the accessory soleus muscle was performed. Currently the patient is asymptomatic and able to participate in the sport of ultra endurance running.

Discussion

The soleus muscle is found in the posterior-medial part of the leg, under the gastrocnemius muscles, together with those forming the sural triceps. It originates in the tibia, fibula and the aponeurosis which cover it and insert in the posterior part of the calcaneus by the Achilles tendon.

The accessory soleus muscle was originally described by Cruveilhier in 1843.¹ The evidence that an accessory soleus

muscle can cause symptoms first appeared in the medical literature in 1965 by Dunn.²

During embryogenesis, the soleus muscle separates in two, developing a supernumerary muscle with its own fascia, artery and nerve, dependent on the posterior tibial artery and nerve respectively. It usually has its own fascia and is completely separate from the accessory soleus muscle.

The incidence of the accessory soleus muscle ranges from 0.5 to 6.0% of the population,³⁻⁵ although recently Koubalchouck et al⁶ estimated that it could be up to 10% and Del Nero⁷ could be up to 11.6%. It usually appears between the second and third decade of life due to a secondary muscle hypertrophy in relation to physical activity of an individual and is more common in men than in women with a ratio of 2:1, excepting in Del Nero et al⁷ series. It is usually unilateral, but Romanus et al⁸ and Yu and Resnick⁹ have described bilateral cases.

Although it may be an incidental finding during imaging performed for an unrelated injury,^{3,8} the typical presentation is a soft mass in the posteromedial distal third of the leg, which increases in size with physical activity especially with

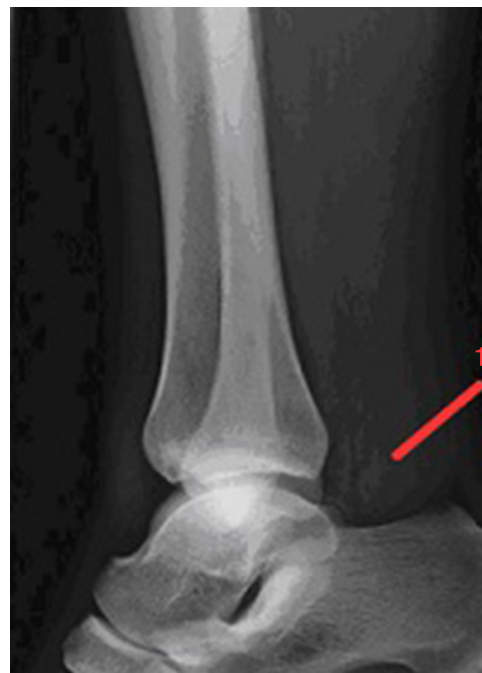

Figure 1 X-ray lateral ankle, obliteration of the Kager triangle for accessory soleus muscle.

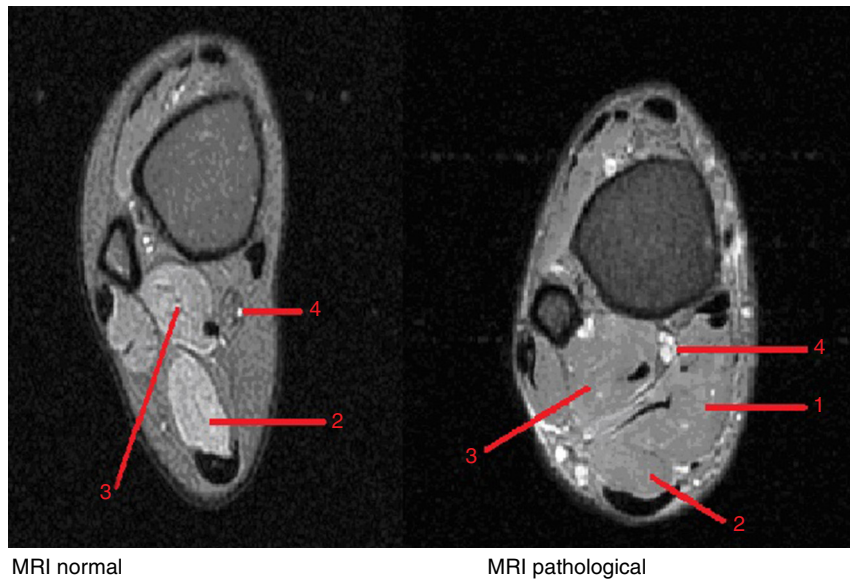

Figure 2 MRI. Comparative axial DP FS. Normal and pathological. 1. Accessory soleus muscle; 2. Soleus muscle; 3. Long flexor thumb; 4. Artery, vein and nerve posterior tibial.

plantar flexion.^{4,5,8} It is accompanied by pain in 67% of cases³ that gets worse with running and jumping.^{4,8,10} These symptoms could be explained by the presence of compartment syndrome chronic caused by an increased size in the accessory muscle during activity. It can also cause a compression

neuropathy of the posterior tibial nerve or claudication due to involvement of the posterior tibial artery.^{5,9,11}

Although less frequent, the following associated conditions have been described: a rigid varus hind-foot with limited dorsiflexion,¹² tarsal tunnel syndrome

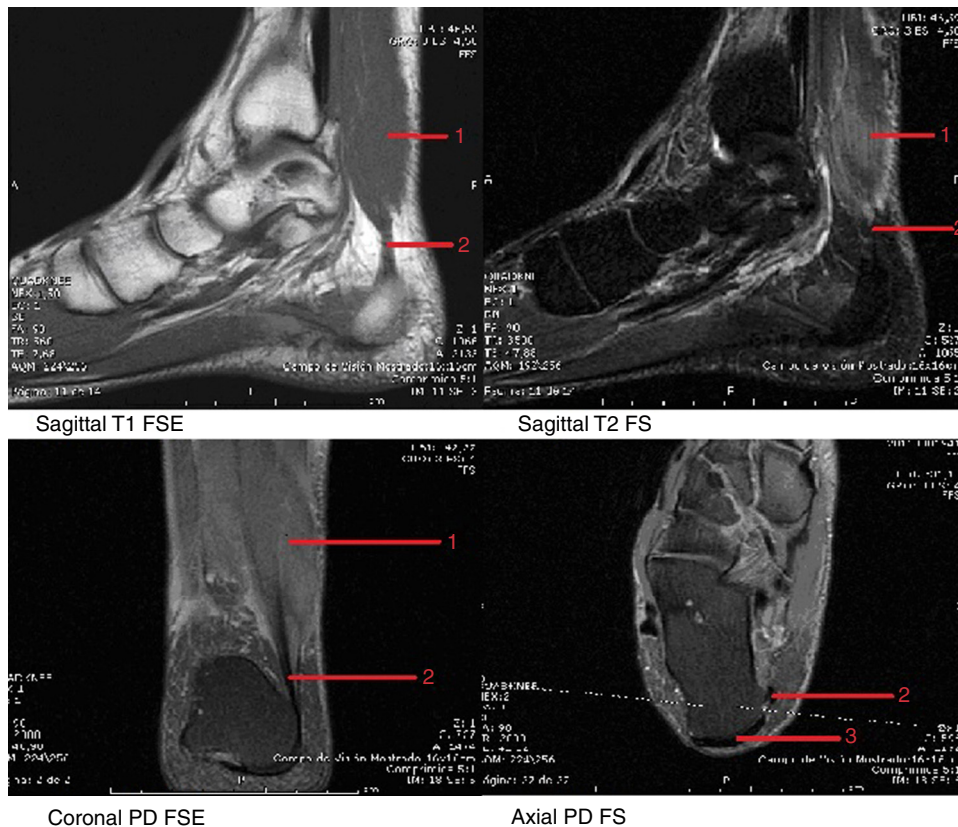


Figure 3 MRI mosaic. 1. Accessory soleus muscle; 2. Accessory soleus tendon; 3. Achilles tendon.

secondary to compression of the tibial nerve¹³ and Achilles tendinopathy.¹⁴ In almost all cases in the lateral X-ray of the ankle, you can see the Kager triangle occupied by a soft tissue mass without associated bone abnormalities.^{2,5,8,9,15} Although the diagnosis is based primarily on clinical suspicion in the presence of a mass that occupies the medial supramalleolar recess, routine use of musculoskeletal ultrasonography as a diagnostic test will confirm a well-defined, retrocalcaneal mass with a similar structure to the muscle striatum and ending at a variable distance from the calcaneus based on their size.^{3,4,9,10}

MRI is the most sensitive and specific test for diagnosis. The image appears as a fusiform or oval, well-defined with its own fascia, and with a signal intensity similar to the normal muscle in both T1 and T2. This allows for a non invasive diagnosis of accessory soleus muscle^{8,9,12} (Fig. 3).

Also, MRI allows for differentiation of other soft tissue pathologies of the posterior ankle that cause pain during exercise in the retrocalcaneal region, including ganglion, lipoma, hemangioma, encapsulated hematoma, synovioma and sarcoma.^{3,4,9,10,16} The accessory soleus muscle usually originates in the distal and proximal posterior tibia, but other possible origins are the deep fascia of the anterior surface of normal soleus fascia and flexor tendon of the toes.^{3-5,16} The insertion distally can be one of the following according Lorentzon et al¹⁷:

- Along the Achilles tendon
- On the top surface of the calcaneus through a tendon
- On the upper surface of the calcaneus
- On the medial surface of the calcaneal with its own tendon (most frequent) (Fig. 3).

The patient in our case report was found to have the last type. Computed tomography is less effective because of the reduced sensitivity to characterize soft tissue injury.^{4,5,9}

Electromyography may show a synchronous electrical activity between the soleus muscle and the attachment.¹

The majority of patients are asymptomatic and need no treatment.

Conservative treatment is based on the use of orthotics, activity modification and physical therapy.^{3,6} If clinical symptoms persist that are consistent with compartment syndrome, intracompartmental pressure should be measured to assess the need for fasciotomy.¹⁸

Total excision of the accessory soleus muscle is reserved for those patients who have symptoms of claudication or nerve compression.^{3,9,19}

Patients usually evolve favorably after surgery remaining asymptomatic.

Recently three patients with an accessory soleus muscle who had pain with exercise but no evidence of compartment syndrome were treated by Deffinis et al²⁰ with Botulinum Toxin A. Although the results are encouraging, the sample size is small and we need to see long-term study results with larger sample sizes.

Knowledge of this condition will prevent unnecessary studies and tests that may delay diagnosis and erroneously treat patients having an accessory soleus muscle.

Acknowledgement

Dra Nancy Fierro and Samantha Fierro.

References

1. Cruveilhier J. *Traité d' anatomie descriptive*. 1st ed. Paris: Bechet Jeune; 1843. p. 262–3.
2. Dunn AW. Anomalous muscles simulating soft tissue tumors in the lower extremities. Report of three cases. *J Bone Joint Surg*. 1965;47:1397–400.
3. Brodie JT, Dormans J, Gregg J, Davidson RS. Accessory soleus muscle. A report of 4 cases and review of literature. *Clin Orthop Relat Res*. 1997;337:180–6.
4. Leswick DA, Chow V, Stoneham GW. Resident's corner. Answer to case of the month #94. Accessory soleus muscle. *Can Assoc Radiol J*. 2003;53:313–5.
5. Palaniappan M, Rajesh A, Rickett A, et al. Accessory soleus muscle: a case report and review of the literature. *Pediatr Radiol*. 1999;29:610–2.
6. Kouvalchouk JF, Lecocq J, Parier J, et al. The accessory soleus muscle: a report of 21 cases and a review of the literature. *Rev Chir Orthop Reparatrice Appar Mot*. 2005;91:232–8.
7. Del Nero FB, Ruiz CR, Aliaga RJ. The presence of accessory soleus muscle in humans. *Einstein*. 2012;10:79–81.
8. Roman B, Lindahl S, Stener B. Accessory soleus muscle. A clinical and radiographic presentation of eleven cases. *J Bone Joint Surg*. 1986;68:731–4.
9. Yu JS, Resnick D. MR imaging of the accessory soleus muscle appearance in six patients and a review of the literature. *Skeletal Radiol*. 1994;23:525–8.
10. Ekstrom JE, Shuman WP, Mack LA. MR imaging of accessory soleus muscle. *J Comput Assist Tomogr*. 1990;14:239–42.
11. Trosko JJ. Accessory soleus: a clinical perspective and report of three cases. *J Foot Surg*. 1986;25:296.
12. Bonnel J, Cruess RL. Anomalous deformation of the soleus muscle as cause of the fixed equinus deformity: a case report. *J Bone Joint Surg*. 1969;51-A:999–1000.
13. Dos Remedios ET, Jolly GP. The accessory soleus and recurrent tarsal tunnel syndrome: case report of a new surgical approach. *J Foot Ankle Surg*. 2000;39:194–7.
14. Luck M, Gordon A, Blebea J, et al. High association between accessory soleus muscle and Achilles tendonopathy. *Skeletal Radiol*. 2008;37:1129–33.
15. Doda N, Peh WCG, Chawla A. Symptomatic accessory soleus muscle: diagnosis and follow-up on magnetic resonance imaging. *Br J Radiol*. 2006;79:129–32.
16. Assoun J, Railhac J, Richardi G, et al. CT and MR of accessory soleus muscle. Anatomical image. *J Comput Assist Tomogr*. 1995;2:333–5.
17. Lorentzon R, Wirell S. Anatomic variations of the accessory soleus muscle. *Acta Radiol*. 1987;28:621–9.
18. Peterson DA, Stinson W, Carter J. Bilateral accessory soleus: a report on four patients with partial fasciectomy. *Foot Ankle*. 1993;14:2848.
19. Rossi R, Bonasia DE, Tron A, et al. Accessory soleus in the athletes: literature review and case report of a massive muscle in a soccer player. *Knee Surg Sports Traumatol Arthrosc*. 2009;17:990–5.
20. Deffinis C, Issno-Horobeti ME, Blaes C, et al. Le muscle soléaire accessoire douloureux chez le sportif: trois premiers cas traités par toxine botulique A. *Ann Phys Rehabil Med*. 2012;55 Suppl. 1:74.